



COMPARISON OF THE EFFECTIVENESS OF PHYSICAL TRAINING AND EXTRACT OF SOURSOP LEAF TO HISTOPATHOLOGY OF ABDOMINAL AORTA FOAM CELLS IN HIPERCOLESTEROLEMIA-DIABETES RAT

THA Nai¹, R Yulianti^{2*}, W Likhayati³, Y Setyaningsih⁴

¹Medical Faculty, UPN Veteran Jakarta, Jakarta, Indonesia

²Anatomic Pathology Department, Medical Faculty, UPN Veteran Jakarta, Jakarta, Indonesia

³Histology Department, Medical Faculty, Gunadarma Jakarta, Jakarta, Indonesia

⁴Parasitology Department, Medical Faculty, UPN Veteran Jakarta, Jakarta, Indonesia

*Corresponding author : dr.retnoyulianti@yahoo.com

ABSTRACT

Background: Diabetes mellitus has become a public health problem globally. Type 2 diabetes mellitus, caused by lifestyle and high lipid diet, is the most common form. Hypercholesterolemia-diabetes is able to create endothelial injury that results in formation of atherosclerosis, starting with formation of foam cells.

Objective: This research aimed to see the effectiveness of physical training and soursop (*Annona muricata*) leaves extract in lowering the amount of foam cells.

Methods: This research was an experimental study which used the post test-only control group design with 35 Wistar strain rats which were randomly divided into 7 groups, each consisting of 5 rats. K1 was given standard diet, K2 was given atherogenic diet and alloxan, while K3, K4, K5, K6, and K7 were given atherogenic diet, alloxan, and different treatments based on designed group. K3 was given simvastatin, K4 was given metformin, K5 was given physical training, K6 was given soursop leaves extract (SLE), and K7 was given both physical training and SLE. The rats were euthanized after three weeks and aorta was taken to be made into histology slides for foam cells observation.

Results: The result of Kruskal-Wallis and Mann-Whitney Post-Hoc Test showed significant difference ($p < 0,05$) between K2 and K5, K6, K7 while it no significant difference ($p > 0,05$) between K3, K4 and K5, K6, K7.

Conclusion: Physical training, SLE, and the combination of both have a role in lowering formation of foam cells in atherosclerosis.

Keywords : Diabetes, foam cells, hypercholesterolemia, physical training, soursop leaf extract

Received Jun 20, 2020 ; Revised Dec 24, 2020 ; Accepted Dec 25, 2020

INTRODUCTION

Hypercholesterolemia is a state of increased blood cholesterol levels above normal. Diabetes mellitus (DM) is a metabolic disease characterized by excess blood sugar caused by pancreatic disorders to produce insulin, insulin activity, or both.[1]

The homozygous hypercholesterolemia may increase the risk of death at 4.5% of total cases. Badan Penelitian dan Pengembangan Kesehatan said the prevalence of DM in Indonesia increased from 2007 about 1.1% to 2.1% in 2013. Type 2 DM is the most common form of diabetes due to lifestyle.[2]

Hypercholesterolemia and DM could damage vascular endothelial blood vessels by forming a radical causing interference of endothelial protective compounds. This damage eases low-density lipoproteins (LDL) into blood vessels resulting in atherosclerosis, imbalance of food intake and activity output will lead to obesity. The size and amount of fat cells will increase due to obesity leading to ischemia of which area surrounded by fat cells promoting much pro-inflammatory than anti-inflammatory cytokine and then promoting insulin resistance. While insulin resistance occurs, the pancreas will produce increased insulin levels but create more amyloid product causing precipitation and deposition which lead to destruction of pancreas tissue, leading to less insulin secreted thus establishing type 2 diabetes.[3]

Hypercholesterolemia could be treated by simvastatin, which is an inhibitor to HMG-CoA reductase that catalyzes cholesterol biosynthesis. The severity of type 2 diabetes can be reduced through treatment (the drug named metformin could increase peripheral

glucose sensitivity).[1] Therefore, hypercholesterolemia and diabetes also require lifestyle modifications such as physical activity.

The rats that were given physical exercise can reduce the appearance of atherosclerotic plaque.[4] The physical exercise will reduce lipid profile through increased ATP Binding Cassette Transport A-1 (ABCA1) and increased Liver X Receptor (LXR). The physical exercise given to diabetic rats would increase glucose homeostasis, reduce the glucose/insulin ratio, and increase insulin sensitivity. By lowering cholesterol and blood glucose levels, the risk of atherosclerosis will be reduced.[5]

Lately, many researchers are interested in researching herbal medicines as an alternative to treat hypercholesterolemia-induced DM. This is because the effectiveness is not inferior to conventional medicine, side effects that occur are minimal and the costs are relatively cheap. One of them is the soursop (*Annona muricata*) leaf. The mice that were given soursop leaf extract showed less features of atherosclerosis. The flavonoid content in soursop leaves can inhibit the HMG-CoA reductase enzyme leading to reduce blood cholesterol. The flavonoid content also inhibits cholesterol absorption, increases glucose tolerance, and increases glucose uptake in peripherals, and stimulates insulin release and sensitivity. Flavonoids also prevent LDL oxidation thus lowering risk of atherosclerosis. The formation of atherosclerosis begins with the formation of foam cells such as macrophages containing oxidized LDL.[3,6-8]

Based on the descriptions, this research aimed to study the effect of physical exercise, the administration of soursop leaf extract and the combination of

both to the histopathology of abdominal aortic foam cells in a hypercholesterolemia-diabetic rats model compared with standard treatment of diabetic and hypercholesterolemia which in this study we used metformin and simvastatin, respectively .

MATERIAL AND METHODS

Type of this research was an experimental study and using the post test-only control group design. This research has approved by ethical committee Faculty of Medicine UPN “Veteran” Jakarta. This study was conducted in the laboratory by using treatments for one or more experiment groups, then the results were compared with the control group. This study was conducted on September-November 2018 at the Pharmacology and Therapy Laboratory of the Faculty of Medicine, Padjajaran University, St. Eyckman No. 38 Bandung, West Java and reading the score of results at the Anatomy Pathology Laboratory of the Faculty of Medicine, UPN ‘Veteran’ Jakarta.

Animal

This study used male rats (*Rattus novergicus*) Wistar strain which was bred in Pusat Penelitian Antar Universitas – Ilmu Hayati (PPAU-IH), Institute of Technology Bandung (ITB). The rats were maintained in the Pharmacology and Therapy Laboratory, Faculty of Medicine, Padjajaran University. The number for each group was calculated using the Federer formula. Based on the formula, the minimum amount needed was four samples of each group, but to avoid decreasing the number of samples during the study, the researchers added one to each group, so the rats used in the study were 35 rats for 7 groups.

The Soursop Leaf Extract

Soursop leaves were mashed into flour then soaked in ethanol solution for 24 hours. The solution was then filtered, distilled and evaporated for 6-8 hours to obtain a pure extract preparation. Soursop leaves were taken from Manako plantations, Lembang, West Java. Extraction was conducted in the Pharmacology and Therapy Laboratory, Faculty of Medicine, Padjajaran University.

Procedure

The rats were acclimatized for one week. The rats were then selected based on inclusion and exclusion criteria and further divided into 7 treatment groups : 1) Standard feed (Normal/K1 group); 2) Atherogenic + 125 mg/kgBW feed (Negative Control/K2); 3) Atherogenic feed + alloxan 125 mg/kg + simvastatin 0.9 mg/kg (Positive Control 1/K3); 4) Atherogenic feed + alloxane 125 mg/kg + metformin 45 mg/kg/day (Positive Control 2/K4); 5) Atherogenic feed + alloxan 125 mg/kg + physical exercise for 20 meters/minute for 45 minutes (Treatment 1/K5); 6) Atherogenic feed + alloxan 125 mg/kgBW + soursop leaf extract 150 mg/kgBW/day (Treatment 2/K6); 7) Atherogenic feed + alloxan 125 mg/kg + soursop leaf extract 150 mg/kg/day + physical exercise for 20 meters/minute for 45 minutes (Treatment 3/K7). The inclusion criteria were healthy rat, body weight of 150 – 200 gram, obtained and maintained in the same place. The exclusion criteria were the rats which had deformity or sick before treatment.

After that, K1 rats were given standard feed and K2, K3, K4, K5, K6, K7 mice were given atherogenic feed for five weeks. After five weeks the entire group was checked for body weight and total cholesterol levels and then the rats K2, K3,

K4, K5, K6, K7 were given alloxan and observed for the effects of alloxan for 72 hours later, then all groups of rats were checked for blood glucose levels. After that, all groups of rats were given standard feed. Then, K3 rats were given simvastatin, K4 was given metformin, K5 was given physical exercise, K6 was given soursop leaf extract, and K7 was given physical exercise and soursop leaf extract. All this treatment was carried out for three weeks. After that, all groups of rats were measured again for weight, glucose and cholesterol levels and then terminated. First the rats were anesthetized using 0.05 ml/kg body weight ether by intraperitoneal injection, then terminated using cervical dislocation method. After the termination process, rats from all groups were dissected and abdominal aortic organs were taken to make aortic preparations to observe the histopathological picture of the rat aorta.

Physical Exercise Procedure

Moraes et al used moderate intensity exercise in rats at a speed of 0.6–1.3 km/h in the morning for five days in 10 weeks.[9] Souza et.al used physical exercise in rats for 6 weeks.[10] This study conducted a medium-intensity physical exercise intervention for 3 weeks with a maximum speed of 20 meters/minute for 45 minutes. One initial week was to carry out the treadmill adaptation process with a speed of 5 meters/minute for 15 minutes, followed by 2 weeks with multilevel speeds ranging from 10 meters/minute to 20 meters/minute. In the second week, the first three days a treadmill were carried out at a speed of 10 meters/minute for 30 minutes then the following day a treadmill were carried out at a speed of 11 meters/minute for 30 minutes then the next day a treadmill were carried out at a speed of 12 meters/minute for 30 minutes then

four days. The next step was a treadmill with a speed of 20 meters/minute for 30 minutes and the last week continued with a speed of 20 meters/minute for 45 minutes.

Histopathological Analysis

The number of foam cells was counted at 400 times magnification of 9 fields of view on the longitudinal section of the abdominal aorta in the tunica intima layer stained with Hematoxylin Eosin (HE) staining. Foam cells on HE staining will appear as large cells with a blue nucleus and are on the edge and empty space between the nuclei because the fat will fade/escape. The histological preparations viewed and assessed by two independent observers.

RESULTS

Weight Measurement

Table 1 shows the body weight after being given five weeks of diet and given three weeks of treatment in each group. The average normal bodyweight of mice is 150-200 grams.[11]

Table 1. Weight Measurement

Group	Total Weight (gram (\pm SD))		Weight Changes (gram (\pm SD))
	After being given 5 weeks of diet	After being given 3 weeks of treatment	
K1	160,5 (\pm 16,44)	204,25 (\pm 34,50)	\uparrow 43,75 (\pm 26,51)
K2	330,5 (\pm 53,64)	309 (\pm 34,65)	\downarrow 21,50 (\pm 28,16)
K3	318,5 (\pm 23,01)	332,75 (\pm 58,3)	\uparrow 14,25 (\pm 37,39)
K4	240,75 (\pm 41,88)	206,5 (\pm 42,35)	\downarrow 34,25 (\pm 65,74)
K5	248,25 (\pm 114,66)	246,5 (\pm 48,48)	\downarrow 1,75 (\pm 159,81)
K6	192,75 (\pm 41,97)	155,5 (\pm 94,66)	\downarrow 37,25 (\pm 132,31)
K7	296,25 (\pm 34,50)	261 (\pm 34,89)	\downarrow 35,25 (\pm 19,67)

The results of weight measurements carried out after the induction of a high-fat diet showed that the weight of all groups of rats was above 200 except for K1 (no atherogenic and alloxan diet, only standard diets) and K6. Weight results in each group decreased after three weeks of treatment except for K1 (not given only standard diet treatment) and K3 (given simvastatin) both increased.

Total Cholesterol Measurement

Table 2 shows the total cholesterol level after being given five weeks of diet and given three weeks of treatment in each group. The mean normal total rat cholesterol level is 10-54 mg/dl.[11]

Table 2. Total Cholesterol Measurement

Group	Total Blood Cholesterol (mg/dl (±SD))		Total Cholesterol Changes (mg/dl (±SD))
	After being given 5 weeks of diet	After being given 3 weeks of treatment	
K1	70,75 (±2,36)	72,6 (±4,36)	↑ 1,85 (±3,55)
K2	159,25 (±34,71)	195,75 (±42,19)	↑ 36,500 (±68,04)
K3	200,75 (±45,02)	91 (±9,83)	↓ 109,75 (±50,08)
K4	178,25 (±38,72)	60,57 (±9,97)	↓ 117,67 (±35,09)
K5	158 (±31,44)	62,025 (±13,76)	↓ 95,97 (±39,09)
K6	176,5 (±71,20)	69,25 (±2,39)	↓ 107,25 (±72,52)
K7	168 (±14,09)	69,725 (±9,53)	↓ 98,27 (±6,90)

The study was conducted using mice that were induced by a diet high in fat and alloxan so that it became a model of hypercholesterolemia and diabetes. The success of this fat induction can be seen from the comparison of total cholesterol between the normal group and other groups. It is known from Table 2 that total cholesterol levels in all groups after atherogenic feeding exceeded the normal

limit of 10-54mg/dl. The average total cholesterol level K1 (70.5) is lower than K2 (159.25), K3 (200.75), K4 (178.25), K5 (158), K6 (176.5) and K7 (168). K1 was given a standard diet also experienced an increase in cholesterol above normal, but the increase was not as much as the other groups that were given atherogenic diet. The low total cholesterol of K1 compared to other groups indicated the success of fat induction during the treatment period. Blood cholesterol in all groups decreased after three weeks of treatment in each group except for K2 (not given treatment only atherogenic feed and injected alloxan) which increased.

Blood Glucose Measurement

Table 3 shows blood emission levels after being given five weeks of diet and alloxan also given three weeks of giving to each group. The normal range of blood glucose is 50-135 mg/dl.[12]

Table 3. Blood Glucose Measurement

Group	Blood Glucose (mg/dl)		Blood Glucose Changes (mg/dl)
	After being given 5 weeks of diet	After being given 3 weeks of treatment	
K1	93,25 (±7,18)	75,25 (±5,50)	↓ 18,00 (±7,11)
K2	209,75 (±14,43)	236,5 (±26,90)	↑ 26,75 (±38,22)
K3	119,25 (±16,39)	182 (±64,02)	↑ 62,75 (±80,03)
K4	234,25 (±39,75)	119 (±23,80)	↓ 115,25 (±24,45)
K5	286,5 (±102,21)	105 (±29,67)	↓ 181,50 (±127,16)
K6	228,25 (±35,40)	107 (±17,90)	↓ 121,25 (±40,62)
K7	276 (±92,19)	101 (±39,64)	↓ 175,00 (±85,80)

The study was conducted using rats that were induced by a diet high in fat and alloxan so that it became a model of hypercholesterolemia and diabetes. The

success of this fat induction can be seen from the comparison of total cholesterol between the normal group and other groups. It is known from Table 3 that the blood glucose levels of all groups after atherogenic feeding and injection of alloxan exceeded their normal limits of 50-135 mg/d, except for K1 (no atherogenic and alloxan feeds were given, only standard diet).¹² The mean blood glucose level at K1 (93.25) was lower than the K2 group (209.75), K3 (119.25), K4 (234.25), K5 (286.5), K6 (228.25), and K7 (276). Low glucose levels in a normal group compared to other groups indicated the success of induction of alloxan. Blood glucose in all groups decreased after three weeks of treatment except for K2 (no treatment was given only atherogenic diet and alloxan injected) and K3 (given simvastatin) which increased.

Measurement of Foam Cells

Table 4 shows the amount of foam cell after being given the feed and alloxan for five weeks, also the treatment in each group for three weeks.

Table 4. Foam Cells Measurement

Group	Foam cells	Min	Max
K1	1,05 ($\pm 0,92$)*	0,2	2,2
K2	34,88 ($\pm 4,02$)	5,5	28
K3	14,35 ($\pm 9,61$)*	2,8	21,4
K4	12,5 ($\pm 7,64$)*	28,9	37,6
K5	12,53 ($\pm 14,00$)*	1,8	32,8
K6	10,06 ($\pm 7,88$)*	3	19
K7	6 ($\pm 4,55$)	3,2	13

Table 4 shows histopathologic picture of foam cells seen through a microscope at 400x magnification. In K1 group as normal control that was only given standard feed had the least appearance of foam cells in abdominal aorta, while in K2 group as negative control was only given atherogenic feed,

the appearance of foam cells in the abdominal aorta was the highest. Other than that, the number of foam cells in the simvastatin positive control group (K3) and metformin (K4) and the physical exercise treatment group (K5), soursop leaf extract (K6) and the combination of physical exercise and soursop leaf extract) K7 showed decreased foam cells when compared to negative control. The result shows that there was effectiveness of physical exercise and soursop leaf extract or the combination of both on the formation of atherosclerosis. From the three treatments, the K7 group (combination of physical exercise and soursop leaf extract) showed the least appearance of foam cells among the three other treatments and also when compared with positive control such as simvastatin group (K3) and metformin (K4), the amount of foam cells from K7 group was the least. Less appearance of foam cells in K7 group could be used as an alternative therapy in patients with hypercholesterolemia-diabetes as the treatment to inhibit the formation of atherosclerosis and can also be considered as a therapy to replace the standard of pharmacological drugs.

Histopathology of foam cells

This is a picture of foam cells from abdominal aorta rats that have been given fed for five weeks and given treatment for three weeks on each treatment group.

The foam cell in the HE staining will appear as a large cell with a blue cell nucleus and at the edges, and an empty space between the nuclei because the fat will fade. As shown in Figure 1, K2 group has the highest number of foam cells, while K1 group has the smallest number of foam cells. The depiction of foam cells in the K5, K6, and K7 groups was less than

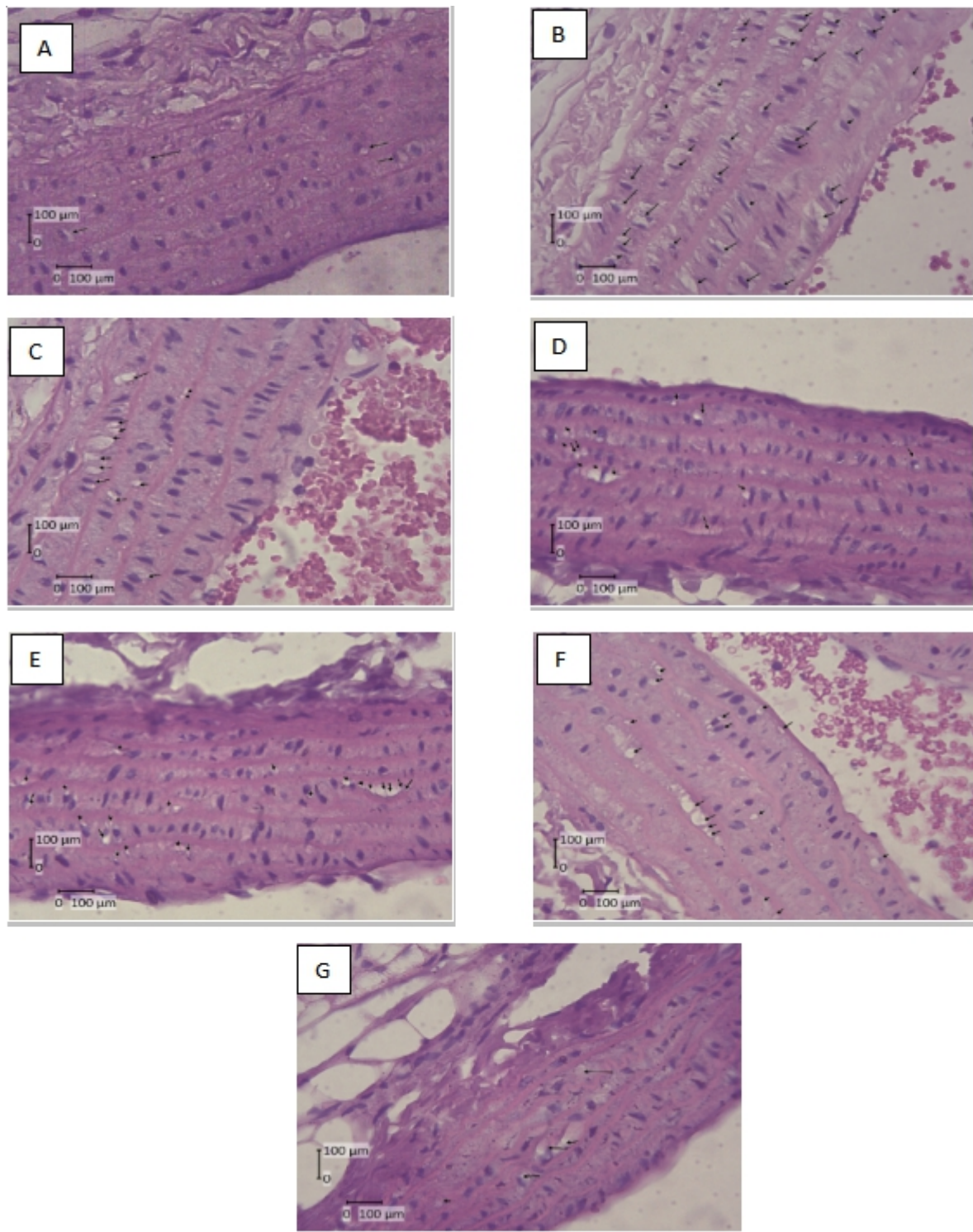


Figure 1. Histopathology of foam cells on an abdominal aortic preparation in hypercholesterolemia-diabetic rats after treatment. A. K1 (Standard Fed). B. K2 (Aterogenic Feed+Alloxan), C. K3 (Aterogenic Feed + Alloxan + Simvastatin), D. K4 (Aterogenic Feed + Alloxan + Metformin), E. K5 (Aterogenic Feed + Alloxan + Physical Exercise (20 meters/minute for 45 minutes) F. K6 (Aterogenic Feed + Alloxan + EDS (150 mg/kg of body weight) G. K7 (Aterogenic Feed + Alloxan + Physical Exercise (20 meters/minute for 45 minutes) and EDS (150 mg/kg of body weight)

➤ = black arrow shows appearance of foam cells.

in the K2 group but did not look much different in the K3 and K4 groups.

Histopathological picture of foam cells in the K7 group can provide information that a combination of physical exercise and soursop leaf extract can be used as an alternative therapeutic effort in patients with hypercholesterolemia-diabetes in inhibiting the formation of atherosclerosis and can also be considered as a standard pharmacological substitution therapy.

Statistical Analysis Results

This study used the Kruskal Wallis test as an alternative test since there were groups which data were not normally distributed. The Kruskal Wallis test showed a significance value of 0.008 which means that there were significant differences in the number of foam cells between the seven groups. To find out the different treatment groups, analysis was continued with the Post Hoc test, the Mann Whitney Test.

Table 5 shows the Mann-Whitney test for each group. In the K1 group compared to the K2, K3, K4, K5, K6, and K7 groups, the p-value was less than 0.05, which means that the histopathological picture of foam cells in the group had a significant difference in effectiveness. In the K2 group compared to the K3, K4, K5, K6, and K7 groups, a p-value of less than 0.05 was obtained, which means the histopathological features of foam cells in the group had a significant difference in effectiveness so that it could be said to be physical exercise, soursop leaf extract and the combination of soursop leaf extract and physical exercise has an effect on decreasing the formation of foam cells in atherosclerosis.

Table 5. Mann-Whitney Post Hoc Test

Group	Group	Mann-Whitney Post Hoc Test (Sig.)
K1	K2	0,021 (*)
	K3	0,021 (*)
	K4	0,021 (*)
	K5	0,042 (*)
	K6	0,021 (*)
	K7	0,021 (*)
K2	K1	0,021 (*)
	K3	0,021 (*)
	K4	0,021 (*)
	K5	0,043 (*)
	K6	0,021 (*)
	K7	0,021 (*)
K3	K1	0,021 (*)
	K2	0,021 (*)
	K5	0,564
	K6	1
	K7	0,386
K4	K1	0,021 (*)
	K2	0,021 (*)
	K5	0,386
	K6	0,564
	K7	0,149
K5	K1	0,043 (*)
	K2	0,043 (*)
	K3	0,386
	K4	0,564
	K6	1
	K7	0,564
K6	K1	0,021 (*)
	K2	0,021 (*)
	K3	0,564
	K4	1
	K5	1
	K7	0,773
K7	K1	0,021 (*)
	K2	0,021 (*)
	K3	0,149
	K4	0,386
	K5	0,564
	K6	0,773

Mann-Whitney Test *= significant (p<0,05)

The K5 group was given atherogenic feed, alloxan 125 mg/kg BW and physical exercise, which was previously carried out with an adaptation process, starting from 5 meters/minute for 15 minutes to 20 meters/minute for 45 minutes. When compared to the K3, K4 groups, K6, and K7, there were no statistically significant differences because

p values were greater than 0.05. The K6 group was given atherogenic feed, alloxan 125 mg/kg BW and soursop leaf extract 150 mg/kg BW. Compared with the K3, K4, K5, and K7 groups, there were no statistically significant differences because p values were greater than 0.05. The K7 group was given atherogenic feed, alloxan 125 mg/kg BW, as well as a combination of soursop leaf extract 150 mg/kg BW and physical exercise, which was previously carried out with the adaptation process, starting from 5 meters/minute for 15 minutes to 20 meters/minutes for 45 minutes. Compared to the groups K3, K4, K5, and K6, there were no statistically significant differences because p values obtained more than 0.05.

DISCUSSION

All groups of rats in this study showed histopathological features in the form of foam cells. Hasanah et.al also showed the same result in the group with atherogenic diet for five weeks would show atherosclerotic lesions in the thoracic aorta of the *Rattus novergicus* male Wistar strain.[13]

The effect of moderate-intensity treadmill physical exercise at a speed of 20 meters/minute for 45 minutes in 3 weeks on the histopathology of abdominal aortic foam cells in a hypercholesterolemia-diabetes mouse model can be seen from the comparison between the groups given physical exercise and the negative control group. The average number of foam cells in the group that are given physical exercise (12.53) was lower compared to the negative group that was only given atherogenic and alloxan feed (34.88) with a statistically obtained p-value of 0.043. The provision of physical exercise had a statistically significant difference with

negative controls whereas when compared with other groups p-values were greater than 0.05. This showed physical exercise has an influence on reducing the formation of abdominal aortic foam cells but the effect does not differ significantly from K3 (simvastatin), K4 (metformin), K6 (soursop leaf extract), and K7 (a combination of physical exercise and soursop leaf extract).

The results of this study were in line with the research of Kadoglou et al in mice who have exercised for 60 minutes/session at a proximate speed of 15 meters/minute, they showed an atherosclerosis plaque which decreased by about 30% with a p-value of 0.01 when compared with the control group and sedentary group.[4] Likewise, Setiyaningsih et al study showed that mice given physical exercise treatment for 30 minutes for 6 weeks obtained p-value <0.001 which means that there are differences in the formation of foam cells when compared with the control group. So it can be concluded that the provision of physical exercise can reduce the appearance of foam cells as an early marker of atherosclerosis.[14]

Physical exercise can reduce morbidity and mortality of atherosclerosis-related disease through direct (cardiovascular) and indirect (risk factor modification) factors such as increasing insulin sensitivity, increasing glucose tolerance, increasing HDL cholesterol levels, reducing triglyceride and LDL cholesterol levels, reducing body weight, and improving cardiovascular function. Recent studies have shown that exercise has beneficial effects by increasing endothelial cell function and providing an atheroprotective feature. Franklin and Hambrecht et al observed that 4 weeks of exercise can reduce coronary

vasoconstriction so that it can increase blood flow. Changes in blood flow cause changes in hemodynamic pressure. It is well known that atherosclerosis involves the effect of frictional forces acting on the cell surface as a result of blood flow (hemodynamic friction pressure). Atheroprotective endothelial cells inhibit adhesion and leukocyte release by reducing the regulation of adhesion and chemotactic molecules while performing other beneficial functions, such as vasodilator production, antioxidant enzymes, growth inhibitors, and anticoagulants. This finding is consistent with the results of other studies in humans and animals which show that regular exercise improves endothelial cell function.[15]

Physical activity also influences the formation of oxidative stress. Oxidative stress can be divided into acute and chronic responses. In acute response, physical activity can increase the formation of free radicals, thereby increasing oxidative stress in the body, whereas in chronic response, regular physical activity can increase the capacity of endogenous antioxidants, thereby reducing oxidative stress in the body. An increase in oxidative stress due to free radicals in acute response arises after the individual performs physical activity for 90 to 120 minutes, while chronic response is obtained after the individual performs regular physical activity for 8 to 12 weeks.[16]

Wei et al used mice in physical activity using treadmill for 30 minutes in 2 weeks show increased expression of LDL receptor (LDLr) genes in the liver.[17] This increase in liver LDLr explains that the occurrence of peripheral LDL cleansing is important in physical activity to decrease cholesterol levels and this also

acts as antiatherogenic property. Besides, there is also an increase of SR-BI about 2-3 times from normal which reverses cholesterol as a benefit of physical exercise. This increase will reduce foam cell formation via lipoprotein modification. Angelis et al, explained that physical exercise given to diabetic rats would increase glucose homeostasis, reduce glucose/insulin ratio, and increase insulin sensitivity. Decreased blood glucose and cholesterol levels will reduce the risk of atherosclerosis.[17,18]

The effect of giving soursop leaf extract with a dose of 150 mg/kg BW/day on the histopathology of abdominal aortic foam cells in hypercholesterolemia-diabetic mice can be seen from the comparison between soursop leaf extract given group and negative control group. The average number of foam cells of the soursop leaf extract given group (10,06) was lower than the negative group which was only given atherogenic and alloxan feed (34,88) and statistically obtained a p-value of 0,021. This means, statistically, the group with the administration of soursop leaf extract had a significant difference with negative control. Whereas, if the p-value is greater than 0,05, this means that there was no significant difference between positive control and negative control. This shows that statistically there was an effect of soursop leaf extract with a dose of 150 mg/kg BW/day in reducing the formation of abdominal aortic foam cells but the effect was not significantly different from K3 (simvastatin), K4 (metformin), K5 (physical exercise), and K7 (a combination of physical exercise and soursop leaf extract).

The results of this study were reciprocal with Arafah et al that soursop leaves with a dose of 100 mg/kg BW, 200

mg/kg BW and 400 mg/kg BW 3 times a day for 60 days were shown a picture of fewer foam cells if compared to a positive control that only induced a high-fat diet.[6] Reciprocal with the research conducted by Rizal that soursop leaf extract can prevent the occurrence of atherosclerosis which induced by high fat foods and propylthiouracil. In line with Maramis et al that the group of Wistar rats on a pork fat diet for 14 days and continued with soursop leaf extract for 14 days did not show a microscopic picture of aortic foam cells of Wistar rats. The effect of soursop leaf extract in reducing the appearance of foam cells as an early marker of the formation of atherosclerosis is through changes in risk factors such as reducing hypercholesterolemia, diabetes, and also preventing oxidation processes.

Florence et al explain that the administration of *Annona muricata* extract can reduce blood glucose levels because it contains hypoglycemic compounds namely tannins and flavonoids. Adeyemi et al reported this plant can act through increasing the proliferation of beta-cell islet so that it can increase insulin levels. Flavonoids also have hypoglycemic effects by several mechanisms, namely by inhibiting glucose absorption, increasing glucose tolerance, increasing insulin sensitivity, stimulating insulin release or acting like insulin, increasing glucose absorption by peripheral tissues and regulating enzymes that play a role in carbohydrate metabolism. Other studies more specifically mention that the quercetin compound, a type of flavonoid from the flavonol subclass, has the potential to be a hypoglycemic agent through an inhibitory mechanism against the alpha-amylase enzyme which plays a role in carbohydrate breakdown. In vitro research also shows that quercetin has the potential to reduce glucose levels by

inhibiting glucose transport by the intestinal GLUT2 and GLUT5 which are responsible for glucose absorption in the small intestine.[16]

Wilcox et al stated that there are saponins in *Annona muricata* that play a role in lowering blood cholesterol levels by inhibiting the absorption of cholesterol in the intestine therefore cholesterol will be removed from the body along with feces. A research study by Messina and Lee et al stated that saponins bind to bile acids and increase the excretion of bile acids in the feces, this causes the highly increased conversion of cholesterol to bile acids to maintain bile acid levels.[19] Consequently, LDLr in the liver will be increased so that an increase in LDL uptake will be accompanied by a decrease in plasma cholesterol levels. One secondary metabolic compound, flavonoids, has been shown to increase LDLr expression. LDLr is negatively correlated to LDL cholesterol. The higher LDLr expression results in lower blood cholesterol level.[19] The increased amount of LDLr causes an increase in the absorption of LDL cholesterol in the blood.[20] Aside for reducing total cholesterol levels, soursop leaves extract can increase HDL cholesterol levels. HDL carries cholesterol from peripheral tissue and break down in the liver. Studies using flavonoids show that an increase in lecithin cholesterol acyltransferase (LCAT) activity. LCAT is an enzyme that converts free cholesterol into cholesterol esters and is important for the maturation of HDL metabolism to be returned to the liver.

Besides the capability to reduce blood glucose and cholesterol levels, soursop leaves extract can also prevent the oxidation process. Quercetin is an active substance from flavonoid classification, that can prevent the LDL oxidation process

by capturing free radicals. Vitamin C also acts as an antioxidant that able to inhibit the formation of LDL oxidation.

The effect of a combination of physical training using a treadmill with a speed of 20 meters/minute for 45 minutes and giving soursop leaf extract with a dose of 150 mg/kg/day on the histopathology of abdominal aortic foam cells in a hypercholesterolemia-diabetic rat model can be seen from the comparison between groups that were given a combination of physical training and soursop leaf extract with a negative control group. The average number of foam cells in the combination group of physical training and soursop leaf extract (6) was lower compared to the negative group which was only given atherogenic and alloxan feed (34.88) with a statistically p-value of 0.021. Giving a combination of physical training and soursop leaf extract had a significant difference statistically with negative controls, but when it was compared with other groups, p values were more than 0.05. This case showed the combination of physical training and soursop leaf extract had a statistically significant effect in reducing the formation of foam cells in the abdominal aorta but the effect did not differ significantly from K3 (simvastatin), K4 (metformin), K5 (physical exercise), and K6 (physical exercise). However, from the total number of foam cells that obtained in the three treatments, K7 group (a combination of physical training and soursop leaf extract) showed the least foam cell image among the three treatments. K7 still had the lowest number compared to both positive controls. Fewer image of foam cells in the K7 group can give information that a combination of physical training and soursop leaf extract can be used as an alternative therapy in patients with hypercholesterolemia-diabetes to prevent the formation of atherosclerosis

and can also be considered as a therapy to replace the standard of pharmacological drugs.

CONCLUSION

Physical training, soursop leaf extract and the combination of both of them had significant effect in reducing the histopathological image of abdominal aortic foam cells in hypercholesterolemia-diabetic mice.

REFERENCES

1. Perkeni. Konsensus pengelolaan dan pencegahan diabetes melitus tipe 2 di Indonesia. 2015.
2. Balitbangkes BP dan PK. Riset Kesehatan Dasar (Riskesdas) 2013.; 2013.
3. Vinay Kumar, Abul K. Abbas NF. Robbins and Cotran P.; 2005.
4. Kadoglou, NPE, Kostomitsopoulos, N, Kapelouzou A, Moustardas, P, Katsimpoulas, M, Giagini, A, Dede, E, Boudoulas H, Konstantinides S, Karayannacos, PE, & Liapis C. Effects of exercise training on the severity and composition of atherosclerotic plaque in apoe-deficient mice. J Vasc Res. 2011;43:347-356.
5. Cao QY, Zhang A, Cai J, et al. Autophagy regulates the cell cycle of murine hematopoietic stem and progenitor cells in a nutrient-

- dependent manner. *Exp Hematol*. 2014;1-14.
doi:10.1016/j.exphem.2014.11.002
6. Arafah, SB, Badiri, I, & Ridwan M. Pengaruh Pemberian Ekstrak Daun Sirsak (*Annona Muricata* L.) Terhadap Gambaran Histopatologi Aorta Tikus Wistar (*Rattus Norvegicus*) Jantan Yang Diberi Diet Tinggi Lemak.; 2016.
 7. Brachmachari G. Bio-flavonoids with promising antidiabetic potentials: A critical survey. *Chall Scope Nat Prod Med Chem*. 2011;37/661(2):187-212.
 8. Taylor L. Herbal secret of the rainforest: technical data report for graviola *Annona muricata*, Second Edition. Sage Press Inc.
 9. Moraes-Silva, IC, Silva, KAS, Irigoyen, MC, Mostarda, C, Santos, F, Moreira, ED, Angelis, K, & Farah V. Preventive role of exercise training in autonomic, hemodynamic, and metabolic parameters in rats under high risk of metabolic syndrome development. *J Appl Physiol*. 2013;114(6):786-791.
 10. Souza, SBC, Flues, K, Paulini, J, Mostarda, C, Rodrigues, B, Souza, LE, Irigoyen MC AK. Role of exercise training in cardiovascular autonomic dysfunction and mortality in diabetic ovariectomized rats. *Am Heart J*. 2007;50(4):786-791.
 11. Smith, JB, & Mangkoewidjojo S. Pemeliharaan, Pembiakan Dan Penggunaan Hewan Percobaan Di Daerah Tropis.; 1987.
 12. D K. Bersahabat Dengan Hewan Coba.; 2004.
 13. Hasanah UA, Asni E, Malik Z, Ismawati. Histopatologi Arteri Koronaria *Rattus norvegicus* Strain Wistar Jantan Setelah Pemberian Diet Aterogenik Selama 5 Minggu. *JOM FK*. 2014;2(1):1-11.
 14. Setyaningsih, R, Laswati, H, Ferdiansyah, Rantam, FA, & Aulanni'am A. Foam-cell signified blood vessel endothel repair and histopatology of abdominal aorta through stem cell allogeneous therapy to rats (*Rattus norvegicus*) with atherosclerosis. *Int J Pharm Clin Res*. 2017;9(1):91-95.
 15. Smith J. Exercise and atherogenesis. *Exerc Sport Sci Rev*. 2001;29(2):49-53.
 16. Iyos RN, Astuti PD. Pengaruh Ekstrak Daun Sirsak (*Annona muricata* L.) terhadap Penurunan Kadar Glukosa Darah. *Majority*. 2013;6(2):144-148.
 17. Wei, C, Penumetcha, M, Santanam, N, Liu, Y, Garelnabi, M, & Parthasarathy S. Exercise might

- favor reverse cholesterol transport and lipoprotein clearance: potential mechanism for its anti-atherosclerotic effects. *Biochim Biophys Acta*. 2005;1723(1-3):124-127.
18. Anita K. Kadar glukosa darah dan malondialdehid ginjal tikus diabetes yang diberi latihan fisik. *Muhammadiyah J Nurs*. 2014:109-116.
19. Wurdianing, I, Nugraheni, SA, & Rahfiludin Z. Efek ekstrak daun sirsak (*Annona muricata* Linn) terhadap profil lipid tikus putih jantan (*Rattus Norvegicus*). *J Gizi Indones*. 2014;3(1):96-101.
20. Wurdianing, I, Nugraheni, SA, & Rahfiludin Z. Efek ekstrak daun sirsak (*Annona muricata* Linn) terhadap profil lipid tikus putih jantan (*Rattus Norvegicus*). *J Gizi Indones*. 2014;3(1):96-101.